

---

# The Utilization of a New Yellow Light Laser (578 nm) for the Treatment of Class I Red Telangiectasia of the Lower Extremities

NEIL S. SADICK, MD, FACP, FAACS\* AND ROBERT WEISS, MD†

\*Department of Dermatology, Cornell-Weill Medical College, New York, New York, and †Department of Dermatology, Johns Hopkins University Medical School, Baltimore, Maryland

---

**BACKGROUND.** A dual-wavelength approach is necessary in order to achieve consistent results when utilizing lasers and intense pulsed light sources to treat red and blue lower extremity vessels. In this regard, short-wavelength technologies (500–800 nm) may be employed to treat red telangiectasia of less than 2 mm on the lower extremities.

**OBJECTIVE.** To demonstrate a new yellow light laser utilizing a copper bromide medium and its potential efficacy in the treatment of red lower extremity telangiectasia of less than 2 mm.

**METHODS.** Forty-six women (mean age 37 years) were treated in two private practice settings with a 578 nm yellow light laser with a circulating cooling window (1–4°C). Class I red telangiectases of the thighs 1.5 mm or less in diameter were considered for treatment. Patients were treated with up to three treat-

ments at 6-week intervals on a 5 cm<sup>2</sup> surgical area of vessels utilizing a fluence of 50–55 J/cm<sup>2</sup>. Results were analyzed by macrophotographic imaging, double-blinded observer evaluation/optical chromatography, and a patient evaluation scale.

**RESULTS.** An average of 1.7 patient treatment sessions produced significant clearing of 75–100% in 71.8% of patients. The mean erythema index showed significant lightening (51–65a+) in the study population. Finally, 76.1% of patients reported great satisfaction with the results of their treatment session.

**CONCLUSION.** A new 578 nm copper bromide (CuBr) yellow light laser produces excellent results in eradicating red telangiectases of the lower extremities that are less than 2 mm in diameter.

---

IMPROVED RESULTS in the laser/intense pulsed light (IPL) treatment of lower extremity blood vessels has been accomplished by a better understanding of photothermal-endothelial interactions as well as by improved technologies directed toward this goal. A major component toward this end has been a better understanding of varied treatment approaches that are necessary in order to efficiently eradicate small red vessels, which are located superficially on the skin surface (telangiectases), versus blue vessels (venulectases) and small reticular veins, which are usually located deeper within the dermal plexus.<sup>1</sup> To this end, short-wavelength laser IPL technologies incorporating short yellow wavelengths between 532 and 600 nm have been found to be most efficient in eradicating small red vessels located on the lower extremities.<sup>2,3</sup>

It is with these considerations in mind that the present study was undertaken in order to evaluate a new yellow light laser (578 nm) (Pro Yellow, Asclepion-Meditech, Santa Ana, California) that utilizes copper bromide (CuBr) as its active medium. The present

study examines its potential efficacy in the treatment of class I red telangiectases less than 1.5 mm in size.

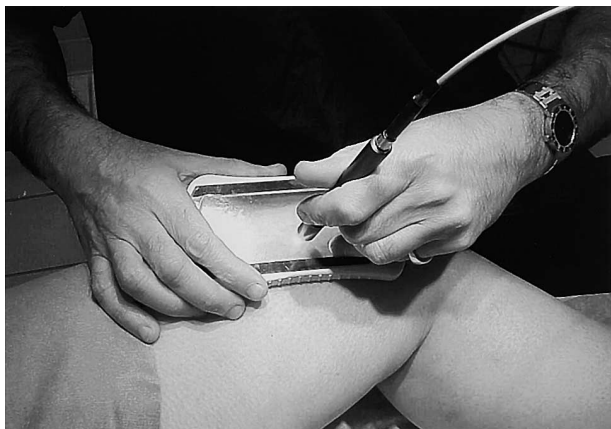## Research Design

Forty-six women (mean age 37 years) with Fitzpatrick skin types I–IV were treated with a 578 nm yellow light laser employing a static circulating cooling window (1–4°C) (Figure 1). Cooling was applied for 1 minute prior to treatment and during treatment. All patients were off hormone therapy for at least 6 weeks prior to entrance into the study. Class I red telangiectases located on the thighs and 1.5 mm or less in diameter were considered for treatment. Vein diameter was measured by a vein gauge device. Treatment parameters were as follows: fluence 50–55 J/cm<sup>2</sup>, spot size 1.5 mm, on-time 300 msec, off-time 75 msec. The number of treatments required in an attempt to produce 100% clearing of a 5 cm<sup>2</sup> grade of vessel was analyzed. A maximum of three treatments were performed at 6-week intervals. Lesser improvement in terms of reducing vessel number and size was evaluated on the following scale: A, 75–100% clearing; B, 50–75% clearing; C, 25–50% clearing; D, 1–25% clearing; E, worse or no change. Treatment was assessed by macrophotographic digital imaging by two

---

N.S. Sadick, MD, FACP, FAACS and R. Weiss, MD have indicated no significant interest with commercial supporters.

Address correspondence and reprint requests to: Neil S. Sadick, MD, FACP, FAACS, 772 Park Ave., New York, NY, 10021.



**Figure 1.** Technique for treatment of class I red telangiectasia employing the 578 nm CuBr laser incorporating a visual circulating cooling window (1–4°C) through which the laser beam is aimed.

double-blinded observers (B.G., T.D.). Erythema reduction was confirmed by optical chromatography. No compression modalities were used in this study.

Patients were examined at 1 month and 3 months after treatment. Complication profiles were monitored at each patient visit.

Patient questionnaires were filled out at the end of the treatment protocol. The results were self-evaluated as G = greatly satisfied, S = somewhat satisfied, M = moderately satisfied, N = not satisfied.

## Results (Table 1)

In this study the 578 nm CuBr laser at a mean fluence of 53 J/cm<sup>2</sup> produced 75–100% clearing in 71.8% of patients after a mean of 1.7 treatments, as documented by clinical and photographic evaluation (Figure 2). In the author's clinical experience at least 75% of vessels must be eradicated in order for significant patient satisfaction to be achieved.

The colorimeter measures the redness (a+), greenness (a–), yellowness (b+), and blueness (b–) of a given target chromophore [ie, oxygenated (red) versus deoxygenated (blue) hemoglobin] on a 0–100 scale (lighter→darker hue). The mean erythema index showed significant lightening (51–65 a+). Only two patients did not have significant lightening as manifested by this technique. Two patients with significant vessel clearing (grade A, 75–100%) are illustrated in Figures 3 and 4. Red vessels responded with the greatest efficacy, while blue vessels were refractory to treatments.

Side effect profiles as documented in the present study were minimal. Two of the study patients (4.4%) developed mild epidermal crusting that healed spontaneously without scarring. Three patients (6.5%) devel-

oped temporary hyperpigmentation, which resolved in all cases when examined at the end of the study. No patient in the present study developed telangiectatic matting as a sequela of the treatment program. In the posttreatment questionnaire, 76.1% of patients evaluated displayed great satisfaction with the results of their treatment program when evaluated 3 months after their final treatment session (Figure 5).

## Discussion

The present study supports the clinical efficacy of treating red telangiectases of the lower extremities with the 578 nm CuBr laser system. The results demonstrate excellent clearance with a minimal number of treatments and an extremely low complication profile.

As has been previously reported, a dual-wavelength approach to laser/IPL treatment of leg vessels produces optimal results with the presently available technologies.<sup>4,5</sup> Shorter wavelengths (500–600 nm) such as the 578 nm yellow light reported in the present study are most efficient in the treatment of class I oxygenated reddish telangiectases, while longer wavelengths (800–1100 nm) are most efficient in treating class II–III deoxygenated blue venulectases and reticular veins. Table 2 outlines the available technologies that may be employed utilizing these treatment principles.

Vessel color, size, thickness, and depth are major parameters that must be considered when choosing an appropriate system for treating lower extremity vasculature. Blue and red vessels of the lower extremities have varied clinical and physiologic structural characteristics (Table 3). The redness or blueness of lower extremity vessels may be determined by several factors, including the Tyndall effect, degree of oxygenated versus deoxygenated blood, vessel size, thickness and depth, and family background variations.<sup>4,6</sup>

Previous short-wavelength technologies have been reported to produce inconsistent results in the treatment of red telangiectasia less than 1 mm in diameter on the lower extremities. The 532 nm KTP laser has been shown to be effective, but produces variable results in this clinical setting.<sup>7–10</sup> Extended pulse durations have been shown to be associated with an increased complication profile. The 585–600 nm pulsed dye lasers (PDLs) have been shown to produce inconsistent results with poor patient satisfaction because of prolonged purpura.<sup>11–18</sup> Newer nonpurpuric-producing technologies employing extended pulse durations are presently being studied. IPL sources (500–1200 nm) have also been shown to produce variable results in this clinical setting. A steep learning curve with high user variability and a relatively high complication profile have reduced the popularity of this technology in the treatment of lower extremity vessels.<sup>19–21</sup>

**Table 1. Yellow Light (578 nm) CuBr Laser Study Results**

Patient	Age	Skin type	Previous sclero	Region	Size	Clearing grade at 1 month	Clearing grade at 3 months	No. of treatments	Optic chromatography	Patient evaluation scale	Side effects
1	24	I	No	Inner thigh	0.2-0.4	A	A	2	55a+/8a+	G	None
2	45	III	No	Inner thigh	0.1-0.4	A	A	2	66a+/12a+	G	None
3	60	III	No	Inner thigh	0.3-0.6	C	C	3	44a+/40a	M	Crusting
4	18	III	Yes	Inner thigh	0.2-0.4	B	A	1	84a+/10a+	G	None
5	27	II	Yes	Inner thigh	0.1-0.6	A	A	1	90a+/12a+	G	None
6	29	III	No	Inner thigh	0.1-0.4	A	A	1	70a+/20a+	G	None
7	40	II	No	Inner/outer thigh	0.1-0.3	B	C	3	49a+/58a+	M	Pigmentation
8	41	II	No	Outer thigh	0.2	A	A	2	57a+18a+	G	None
9	21	II	No	Inner thigh	0.3-1.4	B	A	2	66a+/12a+	G	None
10	41	I	No	Outer thigh	0.2-1.1	A	A	1	82a+/20a+	G	None
11	30	II	Yes	Outer thigh	0.1	B	B	3	72a+/20a+	S	None
12	22	I	No	Outer thigh	0.1	A	A	2	66a+/24a+	G	None
13	36	IV	No	Outer thigh	0.6	B	A	2	80a+/10a+	G	None
14	35	IV	No	Outer thigh	0.3	A	A	3	88a+/16a+	G	None
15	38	III	No	Outer thigh	0.4-1.2	A	A	2	84a+/6a+	G	None
16	40	II	Yes	Inner/outer thigh	0.4-0.8	B	B	3	82a+/78a+	G	Pigmentation
17	41	IV	No	Inner/outer thigh	0.4-1.3	A	A	1	74a+/26a+	G	None
18	44	IV	No	Anterior thigh	0.1	A	A	2	59a+/10a+	G	None
19	29	II	No	Outer thigh	0.1	B	A	1	64a+/13a+	G	None
20	29	III	No	Outer thigh	0.1	A	A	1	89a+/12a+	G	None
21	36	II	No	Outer thigh	0.1-0.8	B	A	2	66a+/24a+	G	None
22	27	II	No	Outer thigh	0.6-1.2	A	A	1	64a+/10a+	G	None
23	31	II	No	Anterior thigh	0.4	A	A	2	89a+/32a+	G	None
24	38	III	No	Posterior thigh	0.1-1.1	B	A	2	68a+/12a+	G	None
25	36	II	Yes	Outer thigh	0.1-0.8	B	B	3	88a+/16a+	G	None
26	49	IV	No	Outer thigh	0.2	A	A	3	72a+/40a+	G	Pigmentation
27	57	III	No	Outer thigh	0.4	A	A	1	60a+/10a+	G	None
28	58	I	No	Outer thigh	0.6	B	A	1	82a+/12a+	G	None
29	30	III	No	Inner thigh	0.4-0.8	A	A	2	86a+/26a+	G	None
30	50	III	No	Outer thigh	0.8	B	B	3	70a+/50a+	S	None
31	52	III	Yes	Inner/outer thigh	0.6	B	A	2	76a+/12a+	G	None
32	41	II	No	Outer thigh	0.2-1.5	A	A	2	82a+14a+	G	None
33	27	III	No	Outer thigh	0.8	A	A	2	81a+/22a+	G	None
34	67	I	Yes	Outer thigh	0.6	A	A	2	76a+/16a+	G	None
35	49	IV	No	Inner thigh	0.6	B	A	2	82a+/19a+	G	None
36	28	III	No	Inner thigh	0.4	A	A	2	77a+/22a+	G	None
37	27	III	Yes	Inner thigh	0.2	A	A	1	86a+/20a+	G	None
38	36	II	No	Inner thigh	0.2-1.2	B	A	1	78a+/18a+	G	None
39	21	III	No	Inner thigh	0.2-0.4	C	B	3	80a+/61a+	S	Crusting
40	29	II	No	Inner thigh	0.1	B	A	2	84a+/18a	G	None
41	46	I	Yes	Inner thigh	0.1	D	D	3	—	S	None
42	26	II	Yes	Inner thigh	0.1	D	D	3	—	S	None
43	36	III	Yes	Inner thigh	0.1	C	C	3	—	M	None
44	40	III	Yes	Inner thigh	0.1-0.2	E	E	3	—	M	None
45	30	II	Yes	Inner thigh	0.1-0.2	D	C	3	—	M	None
46	34	I	No	Anterior thigh	0.1-0.2	B	B	1	—	N	None

**Clearing grade:** A, 75–100%; B, 50–75%; C, 25–50%; D, <25%; E, worse or no change.

**Optical chromatography:** a+, red; a-, green; b-, blueness; b+, yellowness.

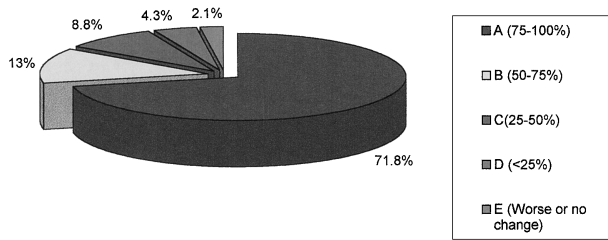
**Patient evaluation score:** G, greatly satisfied; S, somewhat satisfied; M, minimally satisfied; N, not satisfied or worse.

Finally the long-wavelength technologies, that is, 1064 nm Nd:YAG lasers have been found to be refractory in treating red telangiectasia less than 2 mm in diameter.<sup>22</sup> Higher-fluence, short pulse duration op-

tions are now being explored in an attempt to have a monomodal wavelength that is capable of addressing vessels of all color structural characteristics.<sup>23</sup>

The herewithin described 578 nm CuBr laser as doc-

## Clearing Grade



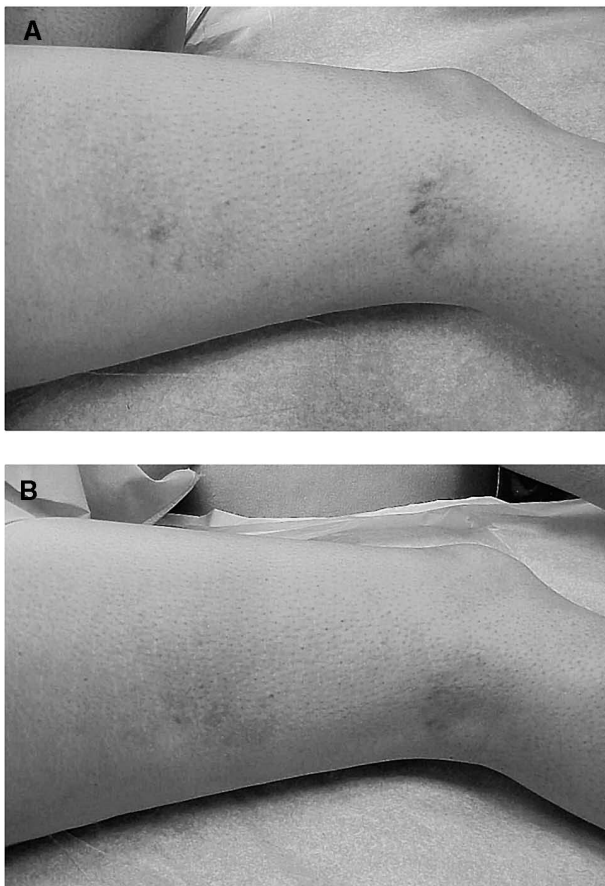**Figure 2.** Distribution of clearing grades ( $n = 46$ ) for patients treated with the 578 nm CuBr laser; 71.8% of patients achieved 75–100% clearing of red vessels less than 2 mm in maximum diameter after an average of 1.7 treatment sessions.

umented by the present study produces consistent results while not being limited by drawbacks associated with the previously described technologies. The ex-

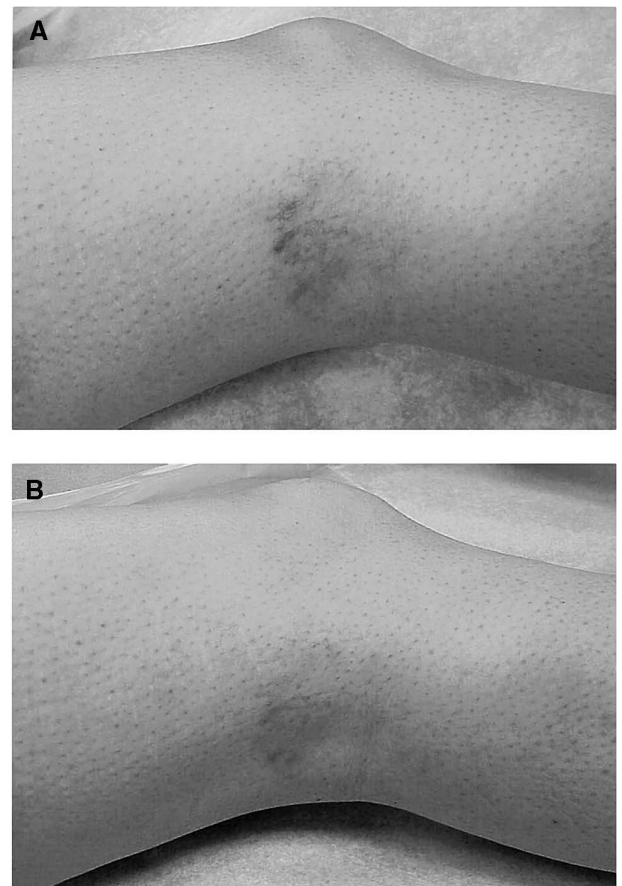
cellent hemoglobin absorption wavelength and high-energy fluences achieved by this technology may contribute to these results.

However, the presently described technology has two drawbacks that must be considered by the laser surgeon. The first is the long time (15–20 minutes) necessary to warm up the laser and the second is the relatively small spot size (1.5 mm), which limits the vessel surface area that can be treated with each laser pulse, increasing the time necessary to carry out each laser treatment. A second-generation technology addressing these issues is presently in development.

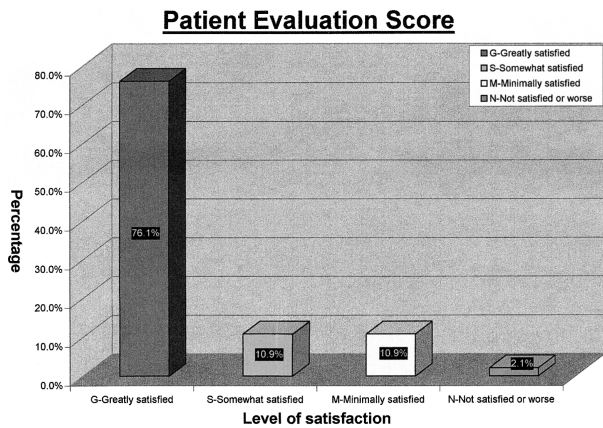
Of note, the present study defined 75–100% clearing of vessels to be a cutoff for successful treatment results. This is corroborated by previous studies as being a necessary cutoff point for successful treatment results.<sup>22,23</sup> This critical improvement parameter is substantiated both by the patient satisfaction scale presented herein as well as the diminution in erythema index as measured by optical chromatography.



**Figure 3.** A) Before and B) after the treatment (3 months) session on the inner thigh with the 578 nm CuBr laser (fluence 53 J/cm<sup>2</sup>) producing more than 75% clearing of the treatment site (maximum vessel diameter 1.5 nm).



**Figure 4.** A) Before and B) after two treatments (3 months) on the lower inner thigh with the 578 nm CuBr laser (average fluence 54.5 J) producing approximately 90% clearing of the treatment site (maximum vessel diameter 2 mm).



**Figure 5.** Patient satisfaction scores 3 months after completion of 578 nm CuBr leg vein study; 76.1% of patients reported great satisfaction with their treatment results.

**Conclusion**

A new 578 nm CuBr yellow light laser produces excellent results in eradicating red telangiectases of the lower extremities that are less than 2 mm in diameter. Efficient clinical photothermolysis with a minimal number of treatments and a low complication profile make this an excellent alternative for treating these difficult to cannulate vessels. A bimodal wavelength approach is

**Table 2.** Lasers/IPL Source Available for Treatment of Small-Vessel Disorders

<400 μm
Intense pulsed light source (500–1200 nm)
Pulsed dye laser (585–600 nm)
KTP laser (532 nm)
Copper bromide laser (578 nm)
>400 μm
Nd:YAG laser (1064 nm)
Diode laser (800 nm)
Alexandrite laser (755 nm)

**Table 3.** Red versus Blue Lower Extremity Vessels

Red Vessels	Blue Vessels
Superficial	Deep
Small diameter	Large diameter
Thin intima	Thick intima
↑ Oxygenated hemoglobin	↑ Deoxygenated hemoglobin
– Tyndall effect	+ Tyndall effect
– Background scatter	+ Background scatter

important in providing efficient clearing of red and blue lower extremity vessels.

**References**

1. Goldman MP, Eckhous S. Photothermal sclerosis of leg veins. *Dermatol Surg* 1996;22:323–30.
2. Dover JS, Sadick JS, Goldman MD. The role of lasers and light sources in the treatment of leg veins. *Dermatol Surg* 1999;25:328–36.
3. Chess C, Chess Q. Cool laser optics treatment of large telangiectasia of the lower extremities. *J Dermatol Surg Oncol* 1993;19:74–80.
4. Sadick NS. A histologic bimodal approach to lower extremity veins. *Cosmet Dermatol* 2000; June:17–30.
5. Sadick NS. A dual wavelength approach for laser/intense pulsed light source treatment of lower extremity veins. *J Am Acad Dermatol* 2000; in press.
6. Reisfeld PL. Blue in the skin. *J Am Acad Dermatol* 2000;42:597–605.
7. Adrian RM. Treatment of leg telangiectases using a long-pulse frequency-doubled neodymium:YAG laser at 532 nm. *Dermatol Surg* 1998;24:19–23.
8. Cisneros JL, Del Rio R, Palou J. Sclerosis and the Nd:YAG Q-switched laser with multiple frequency for treatment of telangiectasias, reticular veins and residual pigmentation. *Dermatol Surg* 1998;24:1119–23.
9. Massey RA, Katz BE. Successful treatment of spider leg veins with a high-energy long-pulse frequency doubled neodymium:YAG laser (Help E). *Dermatol Surg* 1999;25:677–80.
10. Bernstein EF, Kornbluth S, Brown DB, Black J. Treatment of spider veins using a 10 millisecond pulse duration frequency doubled neodymium:YAG laser. *Dermatol Surg* 1999;25:316–20.
11. Alora MB, Stern RS, Arnat KA, Power JS. Comparison of the 595 nm long pulse (1.5 msec) and ultra-long (4 msec) lasers in the treatment of leg veins. *Dermatol Surg* 1998;25:445–8.
12. Bernstein EF, Lee J, Lovvery J, et al. Treatment of spider veins with the 595 nm pulsed dye laser. *J Am Acad Dermatol* 1998;39:746–50.
13. Reichert D. Evaluation of the long pulse dye laser for the treatment of leg telangiectasias. *Dermatol Surg* 1998;24:737–40.
14. Hsia J, Lowery JA, Zelickson B. Treatment of leg telangiectasias using a long pulse dye laser at 595 nm. *Lasers Surg Med* 1997;20:1–5.
15. Hohenietner V, Walther T, Wenig M, Baumier W, Landthaler M. Leg telangiectasia, treatment with a 1.5 ms pulsed dye laser, ice cube cooling of the skin and 595–600 nm preliminary results. *Lasers Surg Med* 1998;23:72–8.
16. West TB, Alster TS. Comparison of the long-pulsed dye (590–595 nm) and KTP (532 nm) lasers in the treatment of facial and leg telangiectasias. *Dermatol Surg* 1998;24:222–6.
17. Goldman MP, Fitzpatrick RE. Pulsed dye laser treatment of leg telangiectasia with and without simultaneous sclerotherapy. *J Dermatol Surg Oncol* 1990;16:338–44.
18. Goldman MP, Martin DE, Fitzpatrick RE, Ruiz-Esparza J. Pulsed dye laser treatment of telangiectasias with and without subtherapeutic sclerotherapy. *J Am Acad Dermatol* 1990;23:23–30.
19. Schroeter CA, Wilder D, Reinkee T, et al. Clinical significance of an intense pulsed light source on leg telangiectasias of up to 1 mm in diameter. *Eur J Dermatol* 1997;7:38–42.
20. Schroeter CA, Neumann HAM. An intense light source: the photoderm versus flashlamp or a new treatment possibility of vascular skin lesions. *Dermatol Surg* 1998;24:743–8.
21. Green P. Photothermal removal of telangiectasias of the lower extremities with the Photoderm VL. *J Am Acad Dermatol* 1998;38:61–8.
22. Weiss RA, Weiss MA. Early clinical results with a multiple synchronized pulse 164 nm laser for leg telangiectasias and reticular veins. *Dermatol Surg* 1999;25:399–402.
23. Sadick NS. Vasculight and other 1064 nm wavelength lasers for treatment of lower extremity veins. *Scope Phlebol Lymphol* 2000; 3:172–8.